

sagemax.com

sagemax®



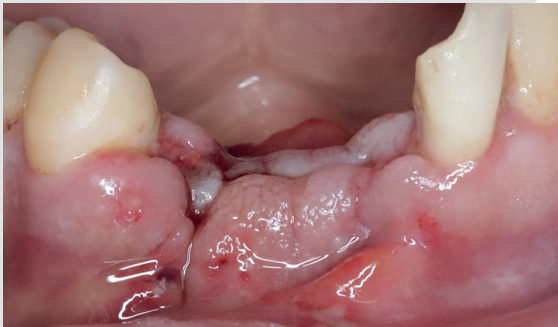
Sagemax experience

NexxZr T Multi
monolithic
by Dr. Mina Magdy

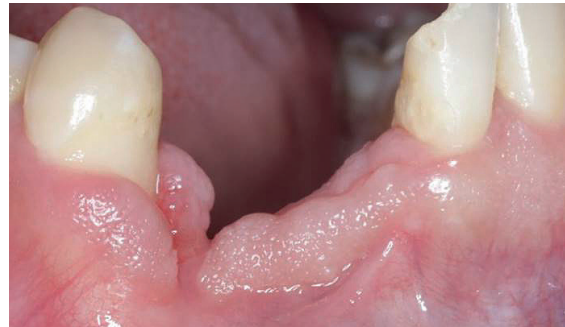NexxZr T Multi monolithic
by Dr. Mina Magdy

Sagemax experience

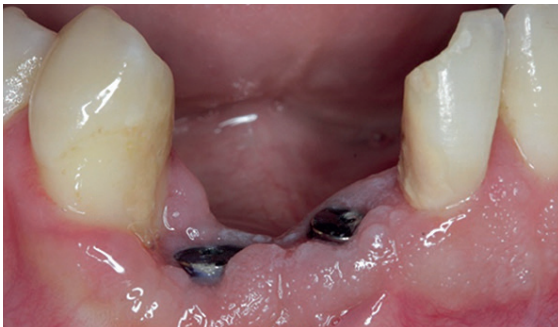Initial situation



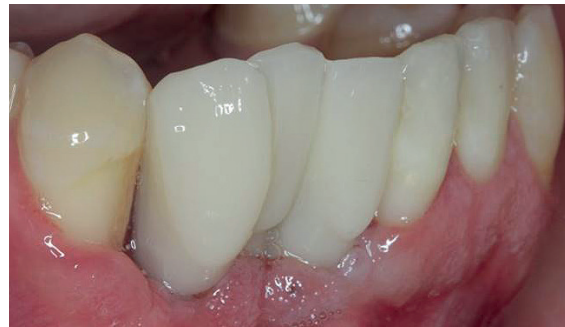One week after dental trauma of teeth 41 - 43.



Three months after the trauma.

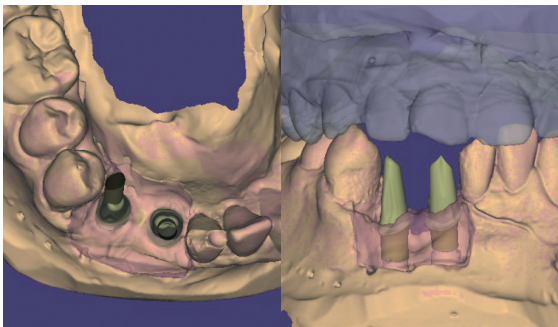


Placement of two implants.

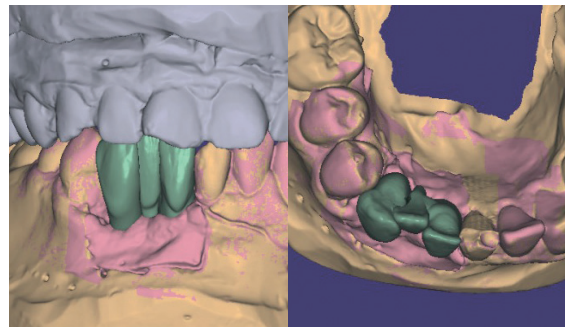


PMMA try-in and temporary restoration.

Design of the restoration

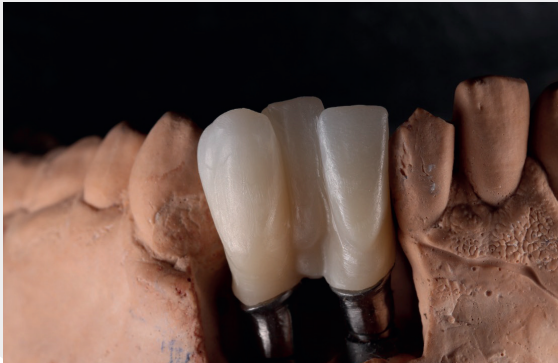

Scanned models and abutments.

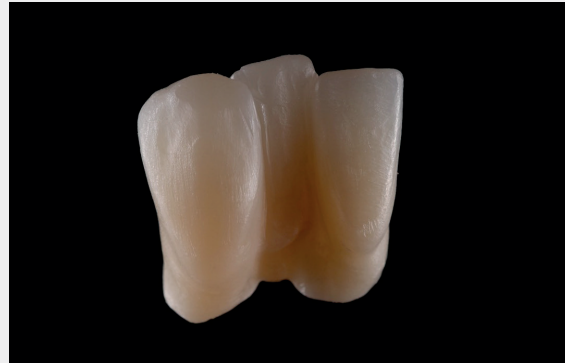

Monolithic design of the 3-unit bridge.

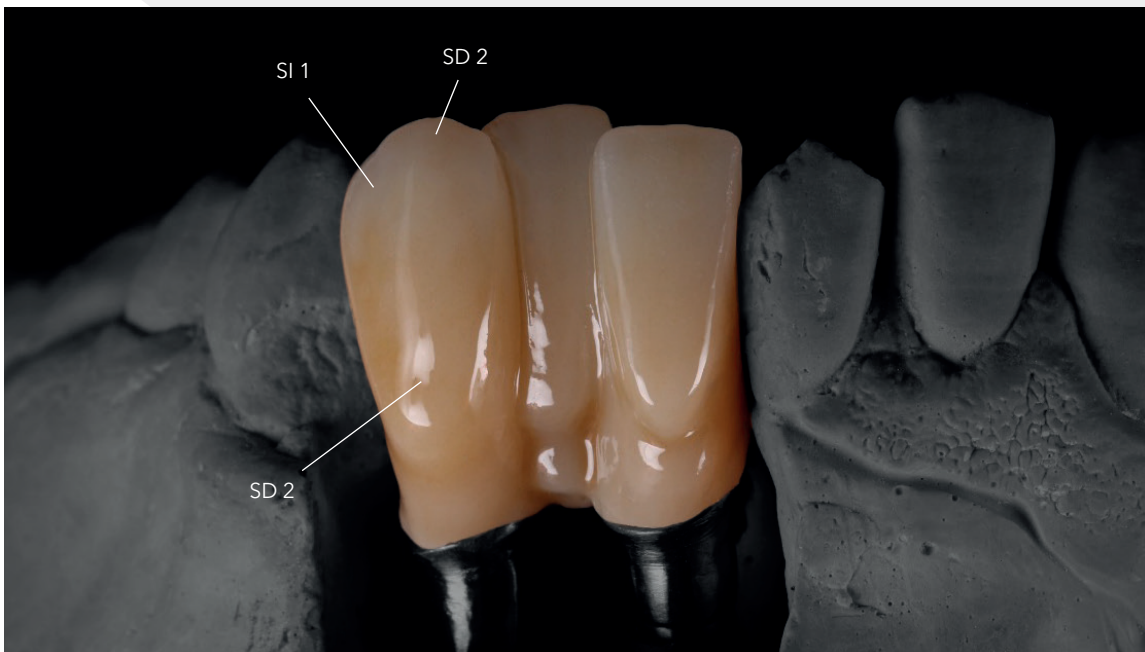
Fabrication of the restoration



Fabrication of the 3-unit bridge from NexxZr T Multi A2.

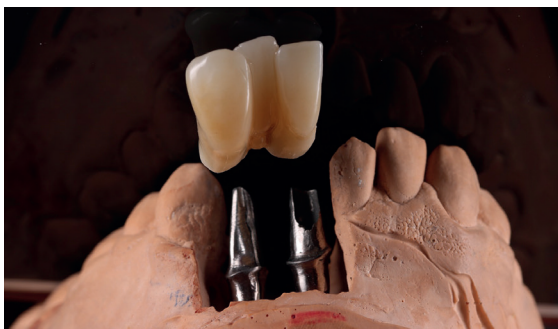

Restoration ready for staining and glazing.

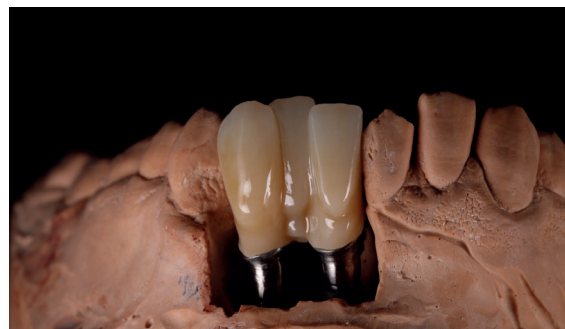

Stained and glazed with IPS Ivocolor (Co. Ivoclar).

Finished NexxZr T Multi restoration

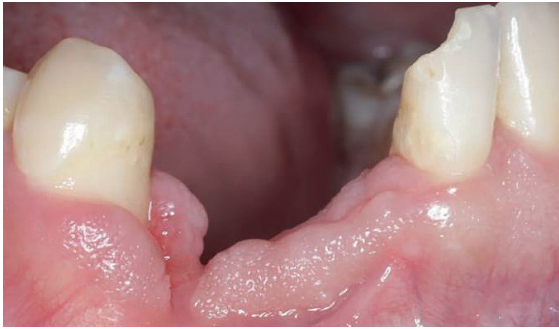

Harmonious shape of the restoration.

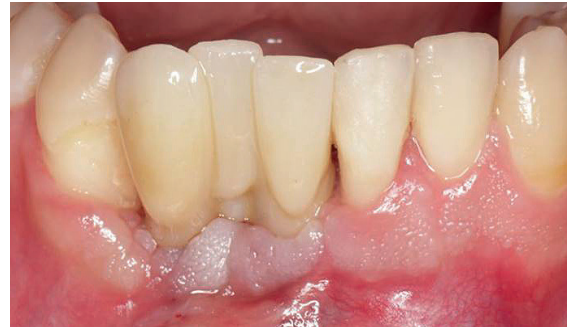

Finished restoration on the model.

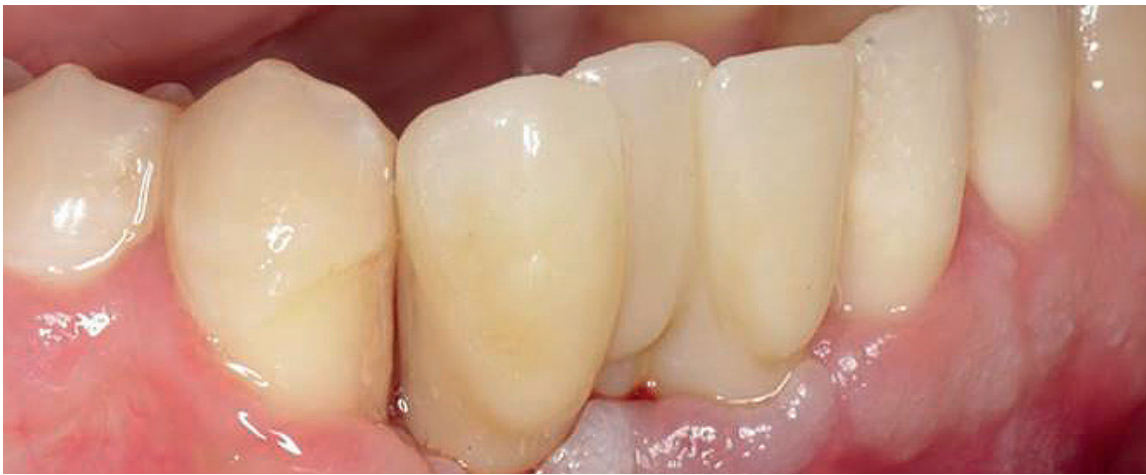Final result



Before.



After.



The restoration blends in harmoniously with the surrounding oral situation.

Dental designers



Dr. Mina Magdy
Dentist, Egypt

Technical Lab Magdy Selim
@ drminamagdyselim



Dr. Fady Sameh
Dentist, Egypt

Contact us
info@sagemax.com

sagemax.com

Follow us
@sagemax.official

