

sagemax.com

sagemax®



Sagemax experience

NexxZr⁺

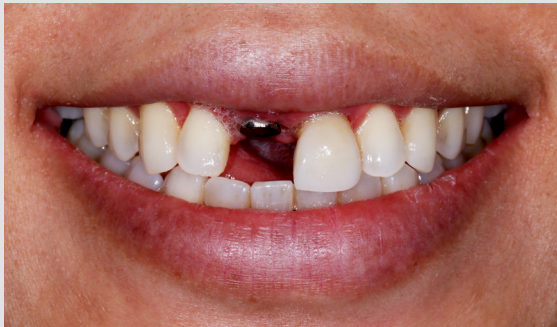1mm facial cut-back

by Sho Kanahara & Dr. C. Lee

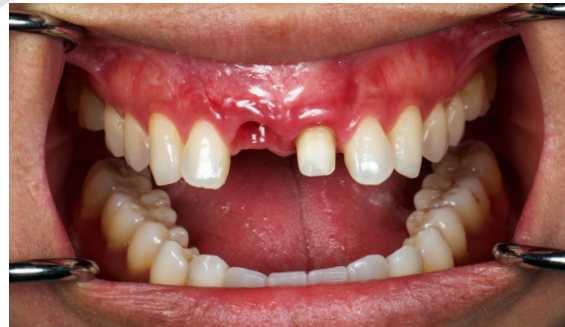NexxZr⁺ 1mm facial cut-back
by Sho Kanahara & Dr. C. Lee

Sagemax experience

Initial situation and preparation

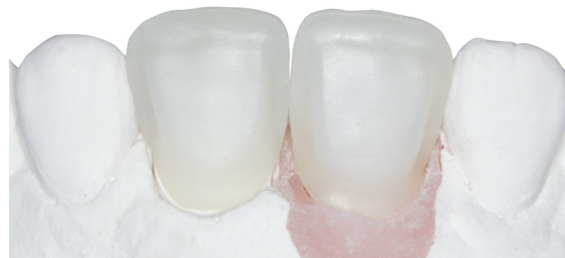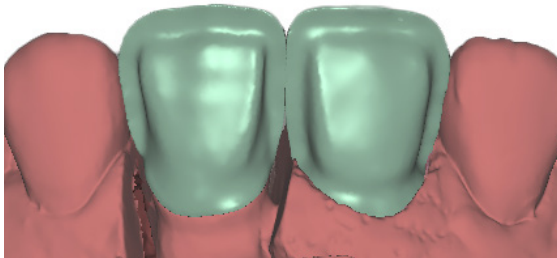


Implant on tooth 11.



After crown preparation of tooth 21.

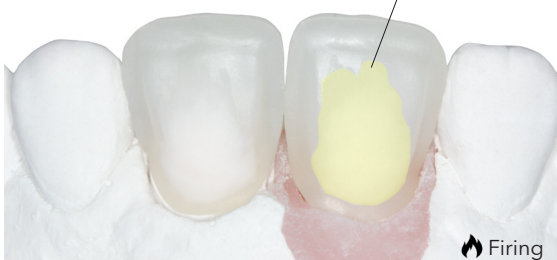Framework design



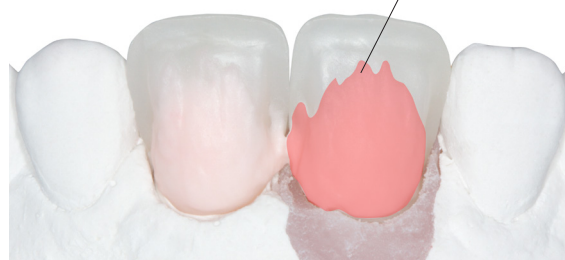NexxZr⁺ was chosen to emphasize natural contrast between incisor and cervical with controlling value on cervical part and to obtain natural translucency.

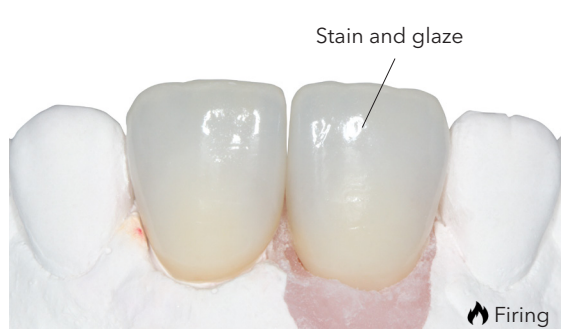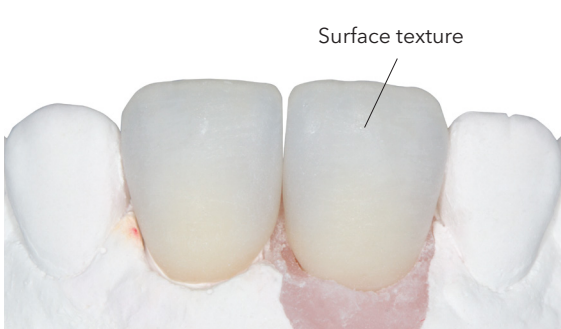
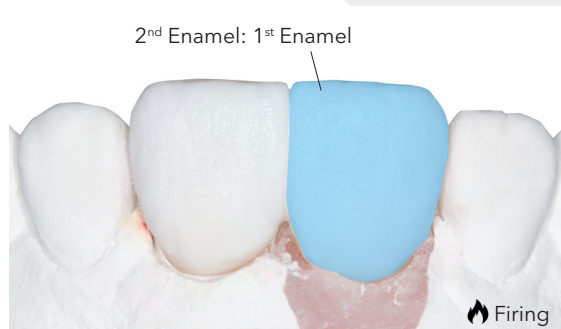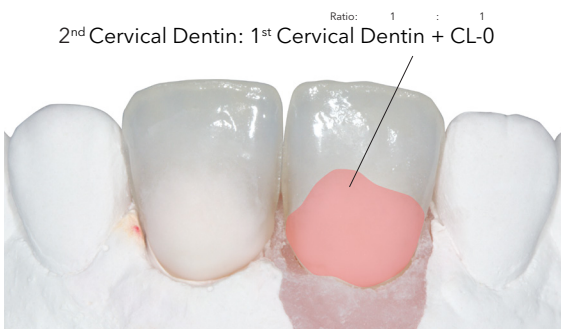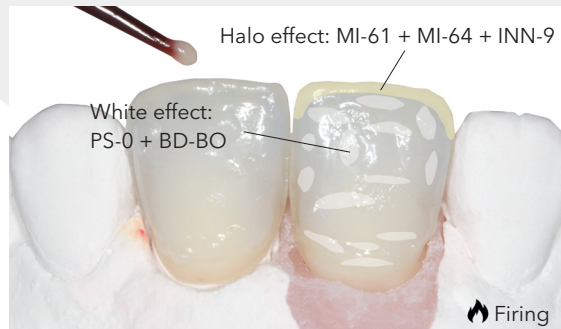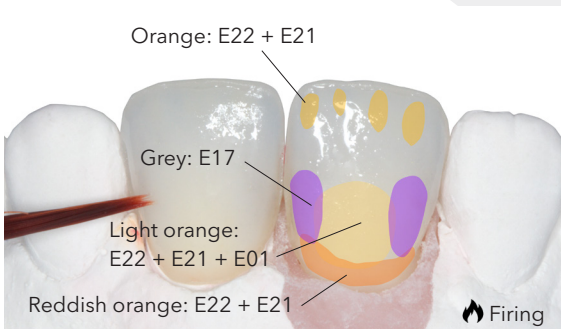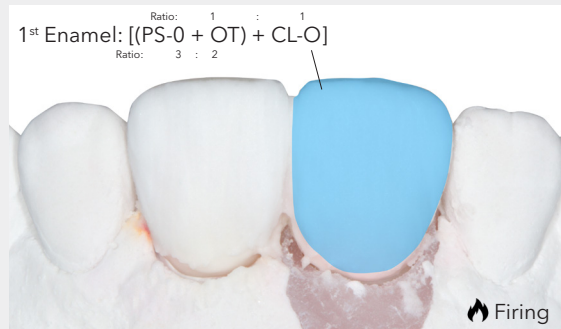
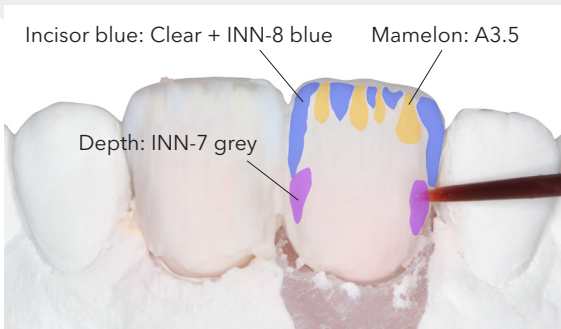
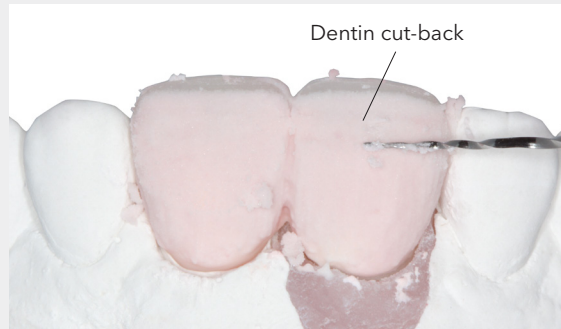
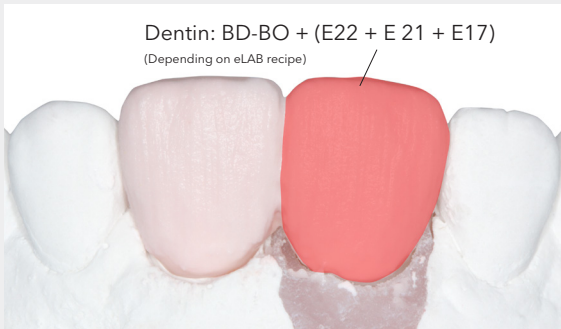Porcelain build-up with Creation ZI-F (Co. Creation Willi Geller) and IPS Ivocolor (Co. Ivoclar)

Cervical brightness adjustment: CW + OD-43

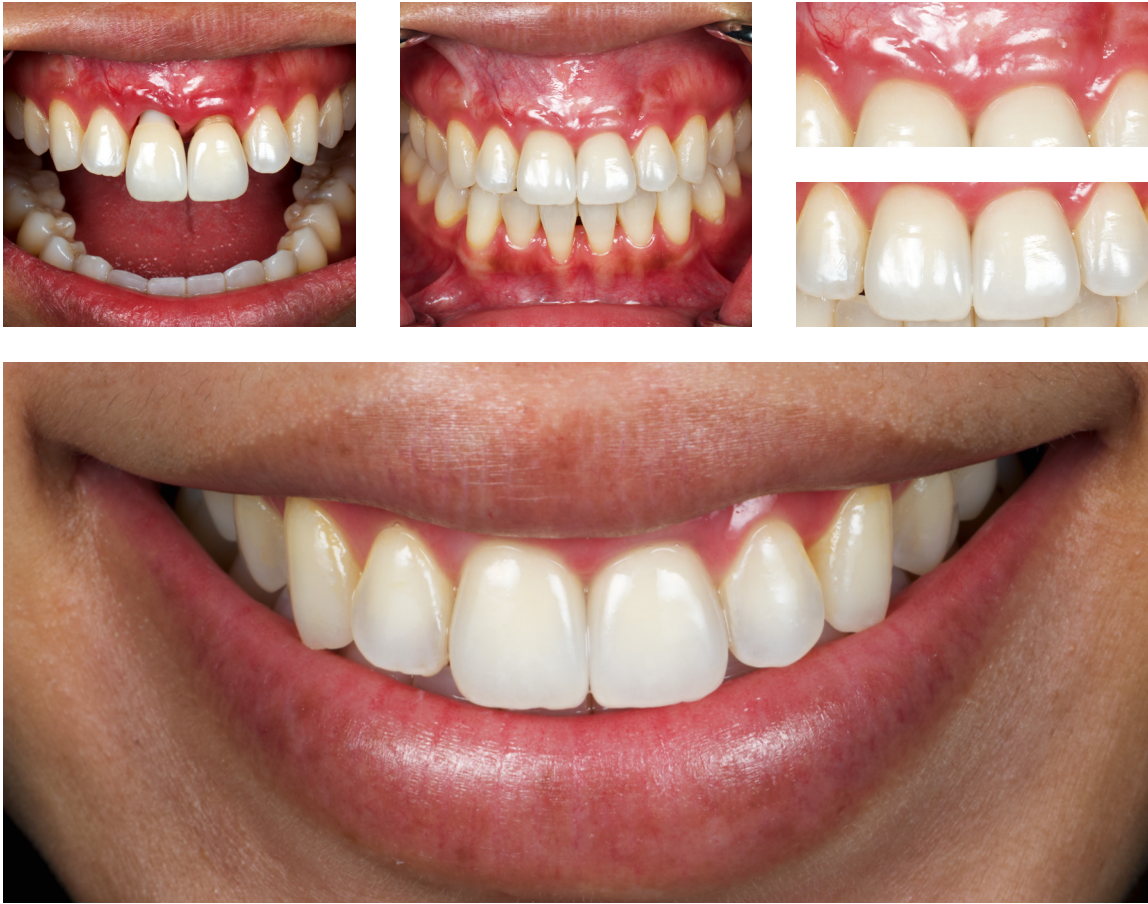

1st Cervical Dentin: BD-BO + (E22 + E21)
(Depending on eLAB recipe)





Final result





The final result is breathtaking and fits perfectly into the surrounding oral cavity.

Dental designers



Sho Kanahara
RDT, MDC, Canada

 sho.kanahara
 sho_kanahara



Dr. Cornell K. Lee
DDS, MDS, FRCD(C), Canada

www.drclee.ca
 dr.cornell.lee

Contact us
info@sagemax.com

sagemax.com

Follow us
@sagemax.official

